

Preliminary Study of the Clinical Outcome of Using PCSO-524 Polyunsaturated Fatty Acid Compound in the Treatment of Canine Osteoarthritis and Degenerative Spinal Diseases

Natwadee Mongkon Kumpanart Soontornvipart*

Abstract

The clinical outcome of PCSO-524 application in the treatment of canine osteoarthritis and spinal disorder was studied at the Small Animal Teaching Hospital, Chulalongkorn University. Eighty-four dogs were included in our study. Thirty-one dogs showed signs of osteoarthritis (OA) in both hip joints and shoulder joints; 33 dogs had OA in stifle joints from cranial cruciate ligament rupture; and 20 dogs had neurological signs of the cauda equina syndrome. All affected dogs were treated by 50 mg/ 10 kg of PCSO-524, PO for twelve weeks. Neurological grading, lameness scores and neurological examinations were evaluated before and after the administration of PCSO-524 for two and four weeks. Radiographic examinations were taken before and after the administration of PCSO-524 for four weeks. The results revealed that a large percentage of dogs experienced improvements in clinical lameness and owner preference although only a few dogs had better radiographic findings. Some of the dogs showed worse radiographic findings, whereas the clinical signs improved. Although the percentages of the improved clinical lameness between the two OA patient groups were high, but were not statistically and significantly different, the radiographic OA findings improved more in patients that had OA in the hip and shoulder joints than in patients that had OA in the stifle joints.

Keywords: dogs, osteoarthritis, PCSO-524, treatment

Department of Veterinary Surgery, Faculty of Veterinary Science, Chulalongkorn University, Bangkok, 10330 Thailand.

**Corresponding author: E-mail: skumpana@gmail.com*

บทคัดย่อ

การศึกษาเบื้องต้นผลของการใช้ PCSO-524 กรดไขมันไม่อิ่มตัวสายยาวกลุ่มโอเมกา 3 ในการรักษาสุนัขที่เป็นโรคข้อและโรคไขสันหลังเสื่อม

ณัฐวดี มงคล กัมปนาท สุนทรวิภาต*

การศึกษาผลของการใช้ PCSO-524 ในสุนัขเป็นโรคข้อเสื่อมและมีปัญหาไขสันหลังเสื่อมที่เข้ารับการรักษา ณ โรงพยาบาลสัตว์เล็ก จุฬาลงกรณ์มหาวิทยาลัย จำนวน 84 ตัว ซึ่งแบ่งเป็นสุนัขแสดงอาการโรคข้อสะโพกและไหล่เสื่อมจำนวน 31 ตัว โรคข้อเข่าเสื่อมจากเอ็นไขว้เข้าขาดจำนวน 33 ตัว และอาการทางระบบประสาทจากโรคควอดราโอโควนาซินโดรมจำนวน 20 ตัว สุนัขได้รับ PCSO-524 ขนาด 50 มก.ต่อน้ำหนักตัว 10 กิโลกรัม สัตว์แพทย์ประเมินเป็นระยะเวลา 12 สัปดาห์ การตรวจระบบประสาท อาการคลินิก ร่วมกับการให้คะแนนอาการทางคลินิกก่อนและหลังการใช้ PCSO-524 สัปดาห์ที่ 2 และ 4 จากการถ่ายภาพรังสีก่อนและ 4 สัปดาห์หลังได้รับ PCSO-524 พบว่า สุนัขป่วยที่ได้รับ PCSO-524 ส่วนใหญ่มีอาการทางคลินิกดีขึ้น เจ้าของส่วนใหญ่พอใจในผลการรักษา มีสุนัขเพียงบางตัวที่มีการเปลี่ยนแปลงทางภาพถ่ายรังสีดีขึ้น นอกจากนี้ยังพบว่า สุนัขบางตัวมีภาพถ่ายรังสีแยกลงในขณะที่อาการทางคลินิกดีขึ้น แม้อาการที่ดีขึ้นหลังได้รับ PCSO-524 ในสองกลุ่มโรคข้อเสื่อม คิดเป็นร้อยละสูงไม่แตกต่างกัน แต่การเปลี่ยนแปลงภาพถ่ายรังสีที่ดีขึ้นพบในกลุ่มโรคข้อสะโพกและข้อไหล่เสื่อมมากกว่ากลุ่มโรคข้อเข่าเสื่อม

คำสำคัญ: สุนัข โรคข้อเสื่อม PCSO-524 การรักษา

ภาควิชาศัลยศาสตร์ คณะสัตวแพทยศาสตร์ จุฬาลงกรณ์มหาวิทยาลัย ปทุมวัน กรุงเทพฯ 10330

*ผู้รับผิดชอบบทความ E-mail: skumpana@gmail.com

Introduction

Osteoarthritis (OA) shows chronic inflammation of joints that causes joint cartilage degeneration, new bone formation (surfaces, margins and capsules of joints) and unstable condition (Ettinger and Feldman, 2010). Although the pathogenesis of OA is not clear, multifactors such as age, breed, hormone, dietary, obesity, abnormal joint mechanism and injury can be a predisposing cause inducing OA (Bruce, 2006; Nganvongpanit et al., 2008; Ettinger and Feldman, 2010). The prevalence of canine osteoarthritis has been recorded to be approximately 20% in dogs that were more than one year old (Johnston, 1997). According to a previous survey data in 100 OA dogs, the percentage of OA joints were identified in 52% of hips, 37% of shoulders, 36% of stifles and 5% of elbows. This showed that hip and shoulder joints were the two most affected joints in dogs.

The damaged joint cartilage cannot return to normal (Wang et al., 2004; Ettinger and Feldman, 2010). Pain and impairment of limb function are the two most consequences of OA. Medication for OA patients supports the improvement of quality of life which is composed of symptom-modifying OA drugs (SYMOA), structural-modifying OA drugs (STMOA) and symptomatic slow-acting drugs for OA (SYSADOA) (Lequesne et al., 1994; Maddison and

Johnston, 2002; Ettinger and Feldman, 2010). Many studies have tried to examine the effects of some biological agents and the combined effect of symptom-modifying and structural-modifying drugs (McNamara et al., 1997; Maddison and Johnston, 2002).

Nutraceuticals have been widely investigated in OA directions because of long term usage and few side effects (Wang et al., 2004; Ettinger and Feldman, 2010). One preference of nutraceuticals in OA dogs is omega-3 essential fatty acids (omega-3 EFAs). Previous study reported on the effects of omega-3 EFAs *in vitro* that omega-3 EFA supplementation not only reduced inflammation but also decreased matrix degradation of the joint cartilage (Curtis et al., 2000; Curtis et al., 2002). The progression of the biomolecular mechanisms of OA patients is obtained and influences the inflammatory process. The considerable pro-inflammatory pathway is connected with cell-membrane-bound arachidonic acid (AA), which is turned into other compounds in the body. These are potent inflammatory substances. This mechanism involves in two major pathways of metabolism: the 5-lipoxygenase pathway (LOX), which leads to the formation of leukotrienes; and the cyclo-oxygenase pathway (COX), which leads to the formation of prostaglandins and thromboxanes, which initiate the progression of cartilage degeneration (Bruce, 2006).

A rich lipid extract from the green-lipped mussel, *Perna canaliculus*, contains a unique group of polyunsaturated fatty acids (PUFAs) that includes eicosatetraenoic acid (ETA). In addition, it is a source of long-chain omega-3 PUFAs, which have been proven to be effectively anti-inflammatory and to develop the clinical outcomes of OA in some researches (Tempel et al., 1900; Sanders, 1993; Curtis et al., 2000). Many reports revealed that omega-3 PUFAs might influence the COX and LOX pathways by decreasing the production of prostaglandins and leukotrienes. This marine extract has been proven to be a natural and less of adverse effects. Moreover, it is an effective inhibitor of the LOX pathway, one of the principal pathways of inflammation in human body. However there have not been many investigations in animals. There have been many prescription diets and commercial omega-3 compound diets which contain omega-3 EFAs, for example, docosahexaenoic acid (DHA) and eicosapentaenoic acid (EPA).

This study was devoted to clinical signs of improvement. Thus, the aim of this pilot study was to observe the clinical effects of the marine oil extract PCSO-524 on canine coxofemoral and shoulder OA by evaluation of clinical lameness, radiographic findings and owner preference.

Materials and Methods

Eighty four, 5-10 years old, 15-30 kilograms dogs participated in this study, were varying in sexes and breeds. Inclusion criteria were 31 dogs showing signs of coxofemoral or shoulder osteoarthritis including joint pain, limb lameness, limited range of motion (ROM) and joint stiffness (Millis et al., 2004). Moreover, the evidence of OA at shoulder or hip joints were diagnosed by radiographs by veterinary radiologists (lateral projection of the shoulder and VD-extended projection of the hip) consisting of periarticular osteophyte formation (shoulder joints: glenoid margins and caudal margin of humeral head, hip joints: cranial part of acetabulum and femoral neck), subchondral bone sclerosis, joint space's narrowing, osseous cyst-like lesions, joint capsule distension and/or periarticular soft-tissue swelling (Dennis et al., 2010; Sirois et al., 2010). Thirty three dogs had osteoarthritis at stifle joints from cranial cruciate ligament rupture and 20 dogs had neurological signs of cauda equine syndrome. All dogs had been treated previously with NSAIDs and glucosamine, which had not led to improvements in clinical signs of lameness and weight bearing. The exclusion criteria of our patients during this study were severe liver, gastrointestinal, urogenital problems and/or pregnancy.

There were three steps of pre-treatment. Firstly, the dogs were generally and physically examined, and clinically and orthopedic examined. Secondly, the lameness scores (Table 1) for OA patients or neurologic grading for cauda equina syndrome were evaluated and recorded. Finally, radiographs of hip, shoulder and/or stifle joints were interpreted and scored by the same veterinary radiologist (Dennis et al., 2010; Sirois et al., 2010).

Table 1 Lameness score criteria (Impellizeri et al, 2000)

Limb lameness score	
0 -	without lameness
1 -	walking with very little lameness and running without lameness
2 -	walking with obvious lameness and running without lameness
3 -	difficulty walking and lameness in running
4 -	non-weight-bearing in walking and lameness in running
5 -	non-weight-bearing in walking and running

The dogs were divided into two groups which were OA patient group which was divided into two subgroups (1: OA lesions at hip and shoulder joints, 2: OA lesions at stifle joints) and cauda equine syndrome group. They received omega-3 fatty acids compound from New Zealand green lipped mussel, *Perna canaliculus*, at the dose of 50 mg per 10 kg daily (50 mg/capsule, MacLab Nelson, New Zealand). All dogs did not receive antibiotic, NASID or others supplement drugs during treatment course. The animals were re-assessed at the 2nd week and 4th week for clinical evaluation (lameness scoring or neurological grading) and at the 4th and 12th weeks for radiographs (radiographic grading). The owner preference were assessed before and 4 weeks after PCSO-524 administration.

The owners of five of the dogs record videotaped the animals walking before and after the administration of PCSO-524 for two and four weeks (optional method). Neurological grading was scored as follows: 0, normal; 1, ataxia with slow proprioceptive reflex; 2, posterior paraplegia with loss of the proprioception in the hind limbs (Impellizeri et al, 2000). Lameness scores and neurological examinations were evaluated by one veterinary orthopedist before and after the administration of PCSO-524 for two and four weeks.

Radiographic examinations were taken before and after the administration of PCSO-524 for four weeks. Radiographic findings included new bone production which included enthesiophytes and osteophytes and was noted at specific anatomical locations in stifle joints. New bone production at a specific site was graded 0 when not identified and 1 to 3 when present, based on the amount of new bone, as indicated by bone density in addition to bone thickness. A total score of 0 indicated no evidence of new bone production within the joint, whereas 3 indicated extensive new bone at all interested sites. Soft tissue changes included joint effusion/capsular thickening, lateral and medial soft tissue thickening, intra-articular osseous fragments and meniscal mineralization. Changes were scored as normal or excessive.

The treated dogs were semi-quantitative graded clinical lameness, neurological signs and radiographic findings and compared in the percentage of improvement, non improvement and progression using chi square test.

Results

Osteoarthritic patients' group: The dogs that had OA were divided into two groups for clinical outcome evaluations: dogs that had OA in their hip and shoulder joints; and dogs that had CrCL ruptures in their stifle joints.

The results are shown in Tables 2, 3, 4 and 5. The results revealed that a large percentage of dogs experienced improvements in clinical lameness and owner preference, although only a few dogs had better radiographic findings. Some dogs showed worse radiographic findings, whereas the clinical signs improved. The percentages of the patients between the two OA patient groups that had improvement of clinical lameness were high. The radiographic OA findings improved more in the hip and shoulder joint OA patients than the stifle joint OA patients. The owner preference included being easy to feed, capsule shape, the efficacy of the supplement and the bottle package. These preferences were high among owners who observed an improvement of the clinical signs.

Table 2 Clinical outcome of OA at hip and shoulder joints after four weeks of PCSO-524 administration (n= 31)

Clinical outcomes (%(n))	Not improve		Progress (worse)
	Improve	improve	
Clinical lameness	90.3% (28/31)	9.67% (3/31)	0% (0/31)
Owner preference	87.09% (27/31)	9.6% (3/31)	3.22% (1/31)
Radiographic findings	16.12% (5/31)	77.42% (24/31)	6.45% (2/31)

Table 3 Lameness score of OA at hip and shoulder joints after four weeks of PCSO-524 administration (n= 31)

Clinical outcomes (% (n))	Worse >1 score	No difference	Better 1 score	Better 2 score	Better 3 score
Lameness score	0% (0/31)	9.67% (3/31)	35.48% (11/31)	48.38% (15/31)	6.45% (2/31)
Radiographic score	6.45% (2/31)	77.42% (24/31)	9.6% (3/31)	6.45% (2/31)	0% (0/31)

Table 4 Clinical outcome of OA at stifle joints after four weeks of PCSO-524 administration (n= 33)

Clinical outcomes (% (n))	Improve	Not improve	Progress (worse)
Clinical lameness	87.87% (29/33)	6.60% (2/33)	6.60% (2/33)
Owner preference	90.90% (30/33)	6.60% (2/33)	3.30% (1/33)
Radiographic findings	6.60% (2/33)	87.87% (29/33)	6.60% (2/33)

Table 5 Lameness score of OA at stifle joints after four weeks of PCSO-524 administration (n= 33)

Clinical outcomes (% (n))	Worse >1 score	No difference	Better 1 score	Better 2 score	Better 3 score
Lameness score	6.60% (2/33)	6.60% (2/33)	78.78% (26/33)	6.06% (2/33)	3.30% (1/33)
Radiographic score	6.60% (2/33)	87.87% (29/33)	6.60% (2/33)	0% (0/33)	0% (0/33)

Neurological patient group that had cauda equina syndrome: The outcome of patients that had cauda equine syndrome and that had neurological deficits which included posterior paraplegia, hind limbs ataxia and loss or slow proprioceptive reflex are shown in Table 6. The radiographic examinations were performed to rule out any other bone defects (such as bone tumors at the vertebrae, or osteomyelitis). Two dogs underwent magnetic resonance imaging, which revealed ventral compression of the spinal cord at the level of L7 and S1, without severe neuropathy. The conditions of both dogs improved. After two weeks the paraplegia improved to the point that their conditions were reclassified as ataxia and the dogs were able to walk short distances. The conditions of other dogs, which had been diagnosed to have cauda equina syndrome by the clinical signs (moderate degree of the clinical signs - ataxia) and slow or loss of proprioception, as well as urinary incontinence, also improved. The clinical signs improved within two weeks after the administration of PCSO-524 began. Fifteen of the dogs were able to walk and even run short distances after they began to take PCSO-524. The conditions of three of the patients in this group became worse, or did not improve, during the same time frame of PCSO-524 administration and the owners refused to continue further investigation of the disease.

Radiographic findings (Fig 1) showed both coxofemoral joints subluxation with moderated degree OA in the femoral necks (Morgan's line) before the PCSO-524 administration and the radiographic OA findings seemed to be the same and more smooth at the femoral necks after PCSO-524 for three months.

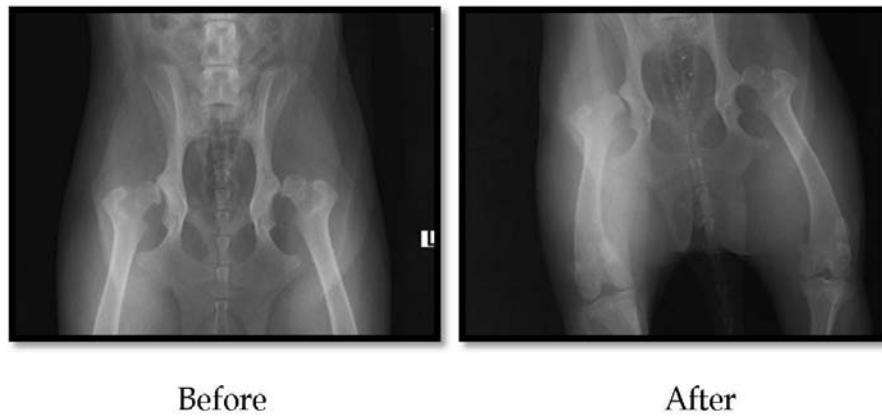

Figure 1 Radiographs showed non-progressive OA at hip joints after PCSO-524 administration for three months.

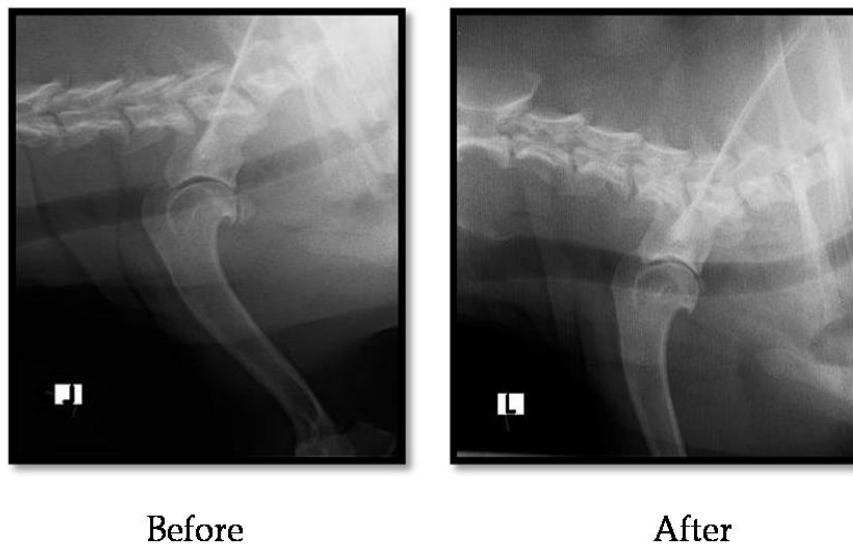


Figure 2 Better radiographic finding was shown after using PCSO 524 at the shoulder joint OA.

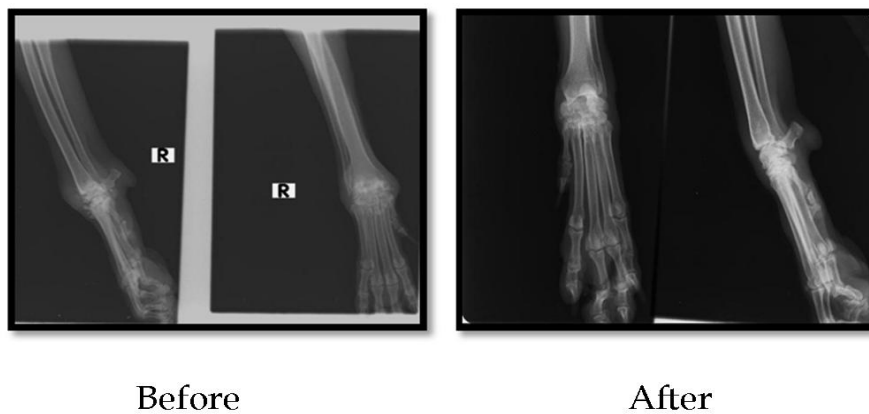


Figure 3 Better radiographic finding was shown after using PCSO 524 at the carpal joint OA.

Table 6 Neurological signs of neurological patients after four weeks of PCSO -524 administration (n= 20)

Clinical outcomes (% (n))	Neurological signs		
	Improve	Not improve	Progress (worse)
Neurological signs	85% (17/20)	10% (2/20)	5% (1/20)
Owner preference	85% (17/20)	10% (2/20)	5% (1/20)

Radiographic calcification (Fig 2) detected at the caudal part of the shoulder joint became smaller and the smooth surface and low grade of sclerosis were detected after three months of PCSO-524 use.

Severe OA with erosive form (Fig 3) of carpal joint arthritis became better clinical and radiographic scoring after PCSO-524 for three months.

Discussion

There is no perfect treatment of choice for OA because the damage to the joint cannot be reversed, but nevertheless medical treatment is necessary to provide a degree of relief and slow or arrest the process of degeneration. The objectives of the treatment in canine OA are to lessen the structural degeneration and to diminish the pain. In the SYMOAD type, non-steroidal anti-inflammatory drugs (NSAIDs) affect the inflammatory pathway by inhibiting cyclo-oxygenase (COX), but in large dosage and/or long-term usage may provide platelet aggregation and gastric ulcers, particularly classical NSAIDs. Although specific COX-2 drugs informed lower side effects, they are not commonly used in Thailand (Nganvongpanit et al., 2008). Recently, nutritional supplementation (nutraceuticals) has played a major role in OA patients because of fewer and less serious side effects than drugs. Oral glucosamine and/or chondroitin sulfate were studied and showed improvement in the clinical signs, moreover chondroitin sulfate may help to restore some of the articular structure (Uebelhart et al., 1998; Uebelhart, 2008). In contrast, a research of placebo-controlled double-blind in OA dogs revealed that veterinarians and owners did not succeed in discerning between placebo or chondroitin sulphate supplemented dogs after twelve weeks follow-up duration (Dobenecker et al., 2002). A recent information of OA pathways has explained an inflammation that leads to change in the articular cartilage. Hence, the development of the nutraceuticals usage has brought to the hope that inhibition of the inflammatory pathway may lead to decreasing cartilage destruction. Omega-3 PUFAs have been become highly interesting in the use of OA management in dogs. An *in vitro* research examined the effects of omega-3 and omega-6 PUFAs on cartilage metabolism. The destruction and the inflammation in cartilage were reduced by omega-3 supplementation (Curtis et al., 2002). EPA and DHA can be extracted from fish. They are usually in fish oil supplements and in prescription diets. Unlike ETA which can be extracted from a small number of food sources. ETA has carbon chain lengths of 20 atoms and four double bonds, which have been found in the New Zealand green-lipped mussel (GLM-*Perna canaliculus*) and it was a predominant PUFA in GLM. The GLM contains not only ETA but also EPA and DHA (Tempel et al., 1990). A previous study presented that the average scores of pain was lesser in the EPA group than the ibuprofen group at the 24th week in 26 OA patients (Stammers et al., 1989). Another investigator compared the efficacy between EPA contained in fish oil (cod liver oil) and NSAID treatment on joint pain and inflammation. There was significantly different advantage to the cod liver oil group compared with the NSAID group in the management of OA (Stammers et al., 1992). On the other hand, there have been more studies about the use of GLM for pain relief in joint diseases. A study in the United Kingdom revealed that 76% of rheumatoid patients and 70% of OA patients had significant improvement in the joint function within three

months (Gibson and Gibson, 1998). The inflammatory mechanism involving OA has extensively been examined. The two important pathways are COX and LOX pathways of AA metabolism (Bruce et al., 2006). The information of GLM components presented a predominant PUFA (ETA) which had AA like structure. As a result of the decreasing LOX products, the PUFAs in GLM might be significant like an anti-inflammatory compound (Treschow et al, 2007). Besides, some studies examined the effect of PUFAs and the reduction of both leukotrienes and prostaglandins was performed (Bruce et al., 2006; Treschow et al, 2007). Many researchers have believed that omega-3 PUFAs may be able to affect the LOX and COX pathways. A report of the GLM usage in OA dogs revealed that the clinical signs significantly improve after six weeks follow-up period (Bierer and Bui, 2002). Recently, there has been an interest in OA biomarkers as primary outcome measures. Although considerable research has been devoted to clinical sign improvement, rather less attention has been paid to OA biomarkers as a way to monitor disease activity and predict disease progression. According to our results, after PCSO-524 was administered to dogs that had OA and cauda equine syndrome, the clinical signs of the conditions (pain, swelling, inflammation, lack of joint mobility) improved, even though few of them had better radiographic findings. During our study of the effect of PCSO-524, we found that the optimum dosage for small and large dogs was as follows:

For large dogs (more than 22 kg) that are severely lame we recommend two capsules in the morning and two in the evening for the first two weeks until their condition improves, then the dose can be reduced to one capsule in the morning and one at night. For small dogs (less than 22 kg) that are severely lame we recommend one capsule in the morning and one capsule in the evening for the first two weeks until their condition improves, then the dose can be reduced to one capsule per day.

The radiographic evaluation and interpretation may be interfered with by the technical exposure of the x-ray machine and radiographic positioning. The standard exposure of the radiographic techniques including the standard technique chart and patient positioning should be standardized in each patient. Further study of the benefits of PCSO-524 for OA treatment is recommended to prove the clinical outcomes, including OA biomarkers (3B3, WF6 and hyaluronic acid), MRI investigation and the effect of the long-term administration of PCSO-524 on OA and other systemic disturbances.

References

- Ettinger, S. and Feldman, E. 2010. Osteoarthritis. In: Textbook of Veterinary Internal Medicine. 7th ed. S. Ettinger. Saunders: St. Louis. 750-761.
- Bierer, T.L. and Bui, L.M. 2002. Improvement of arthritic signs in dogs fed green-lipped mussel (*Perna canaliculus*). J Nutr. 132(6): 1634-1636.
- Bruce, P., Robert, L. and Brain, J.C. 2006. Metabolic

- mechanisms in pathogenesis of osteoarthritis. *J Knee Sur.* 19: 191-197.
- Curtis, C.L., Hughes, C.E. and Flannery, C.R. 2000. Omega-3 fatty acids specifically modulate catabolic factors involved in articular cartilage degradation. *J Biol Chem.* 275: 721-724.
- Curtis, C.L., Rees, S.G. and Cramp, J. 2002. Effects of omega-3 fatty acids on cartilage metabolism. *Proc Nutr Soc.* 61: 381-389.
- Denis, R., Kirberger, R.M., Barr F. and Wrigley, R.H. 2010. Appendicular skeleton. In: *Handbook of Small Animal Radiology and Ultrasound Techniques and Differential Diagnoses.* 2nd ed. E.T. Donald (ed). Philadelphia: Churchill Livingstone/Elsevier. 51-71.
- Gibson, S. L. M. and Gibson, R. G. 1998. The treatment of arthritis with a lipid extract of *Perna canaliculus*: a randomized trial. *Complement Ther Med.* 6: 122-126.
- Dobenecker, B., Beetz, Y. and Kienzle, E. 2002. A placebo-controlled double-blind study on the effect of nutraceuticals (chondroitin sulphate and mussel extract) in dogs with joint diseases as perceived by their owners. *J Nutr.* 132: 1690-1691.
- Johnston, S.A. 1997. Osteoarthritis. *Vet Clin North Am Small Anim Pract.* 27: 699-720.
- Impellizeri, J.A., Tetrack, M.A. and Muir, P. 2000. Effect of weight reduction on clinical signs of lameness in dogs with hip osteoarthritis. *J Am Vet Med Assoc.* 216(7): 1089-1091.
- Lequesne, M., Brandt, K., Bellamy, N., Moskowitz, R., Menkes, C.J., Pelletier, J.P. and Altman, R. 1994. Guidelines for testing slow acting drugs in osteoarthritis. *J Rheumatol Suppl.* 41: 65-71.
- Maddison, J.E. and Johnston, K.J. 2002. Nonsteroidal anti-inflammatory drugs and chondroprotective agents. In: *Small Animal Clinical Pharmacology.* J.E. Maddison (ed.). Saunder: London. 251-269.
- McNamara, P.S., Johnston, S.A. and Todhunter, R.J. 1997. Slow acting disease-modifying osteoarthritis agents. *Vet. Clin. North. Am Small Anim Pract.* 27(4): 863-881.
- Nganvongpanit, K., Suwankong, N., Rungsri, P., Ongchai, S., Kongsawas, S. and Thongtab, A. 2008. *Compendium in canine osteoarthritis.* 1st ed. Chiang Mai. 1-42.
- Rettenmaier, J.L., Keller, G.G., Lattimer, J.C., Corley, E.A. and Ellersieck, M.R. 2002. Prevalence of canine hip dysplasia in a veterinary teaching hospital population. *Vet Radiol Ultrasound.* 43(4): 313-318.
- Smith, G.K., Mayhew, P.D., Kapatkin, A.S., Mckelvie, P.J., Shofer, F.S. and Gregor, T.P. 2001. Evaluation of risk factors for degenerative joint disease associated with hip dysplasia in German shepherd dogs, Golden retrievers, Labrador retrievers, and Rottweilers. *J Am Vet Med Assoc.* 219(12): 1719-1724.
- Sanders, T.A. 1993. Marine oils: metabolic effects and role in human nutrition. *Proc Nutr Soc.* 52(3): 457-472.
- Sirois, M., Anthony, E. and Mauragis D. 2010. Pelvic and forelimb radiographs. In: *Handbook of Radiographic Positioning for Veterinary Technicians.* 1st ed. G. Dave (ed) USA: New York. 26-72.
- Stammers, T., Sibbald, B. and Freeling, P. 1989. Fish oil in osteoarthritis. *Lancet.* 2(8661): 503.
- Stammers, T., Sibbald, B. and Freeling, P. 1992. Efficacy of cod liver oil as an adjunct to non-steroidal anti-inflammatory drug treatment in the management of osteoarthritis in general practice. *Ann Rheum Dis.* 51(1): 128-129.
- Tempel, H.V., Tullekn, J.E., Limberg, P.C., Muskiet, F.A. and Rijswijk, M.H. 1990. Effects of fish oil supplementation in rheumatoid arthritis. *Ann Rheum Dis.* 49(2): 76-80.
- Treschow, A.P., Hodges, L.D., Wright, P., Wynne, P.M., Kalafatis, N. and Macrides, T.A. 2007. Novel anti-inflammatory ω -3 PUFAs from the New Zealand green-lipped mussel, *Perna canaliculus*. *Comp Biochem Physiol B Biochem Mol Biol.* 147(4): 645-656.
- Uebelhart, D., Eugene, J. M., Thonar, A., Delmas, P., Chantrae, A. and Vignon, E. 1998. Chondroitin sulfate on the progression of knee osteoarthritis: a pilot study. *Osteoarthritis Cartilage.* 6: 39-46.
- Uebelhart, D. 2008. Clinical review of chondroitin sulfate in osteoarthritis. *Osteoarthritis Cartilage.* 16: 19-21.
- Wang, Y., Prentice, L.F. and Wluka, A.E. 2004. The effect of nutritional supplements on osteoarthritis. *Altern Med Rev.* 9(3): 275-296.

